

The biofilm decontamination approach for the treatment of periodontal abscess and peri-implantitis (ENGLISH TRANSLATION)

Evelyn Andrea Mancini
Giovan Paolo Pini Prato

Private Practice. Rosario. Santa Fe. Argentina

Periodontology Professor: Accademia Toscana di Ricerca Odontostomatologica (ATRO),
Florence, Italy.

Contact address: 853 Presidente Roca Street, First floor.

2000 Rosario. Santa Fe. Argentina.

Telephone number: +54 341 4407868

Cell phone number: +54 9 341 3719888

E-mail address: ea_mancini@yahoo.com.ar

ABSTRACT

Aim: To show the treatment effect of the biofilm decontamination approach on acute periodontal abscess and peri-implantitis.

Case Reports: An acute periodontal abscess and a peri-implantitis were treated using an **oral tissue desiccation material** that contains a concentrated aqueous mixture of hydroxybenzenesulfonic and hydroxymethoxybenzene acids and sulfuric acid. The material was positioned in the periodontal pockets and around the implant. No systemic or local antibiotics were used in any of the cases. All of the treated cases healed well and very rapidly. The infections were quickly resolved without complications. The momentary pain upon introduction of the material was generally well tolerated and it completely disappeared after few seconds.

Conclusions: The biofilm desiccation approach seems to be a very promising technique for the treatment of acute periodontal abscess and peri-implantitis. The local application of this material avoids the use of systemic or local antibiotics.

Key words: periodontal infection, peri-implant mucositis, peri-implantitis, periodontal therapy

INTRODUCTION

Periodontitis is an infectious disease caused by a bacterial plaque organized in a biofilm¹. The biofilm is a group of microorganisms embedded within a self-produced matrix of extracellular polymeric substance composed of extracellular DNA, proteins and polysaccharides.

The microbial cells growing in a biofilm are physiologically distinct from planktonic cells of the same organism, which, by contrast, are single-cells that may float or swim in a liquid medium. A biofilm can be found on the surface of any hard or soft tissue within the mouth. Its formation begins with the attachment of a microorganism to a hard surface in a wet environment, such as a tooth, through a chemical interaction. The microorganism replicates and recruits other microorganisms in the area, which attach to the same surface and secrete a polysaccharide material called extracellular matrix, an aqueous gel populated by several species of microorganisms.

Bacteria living in the biofilm can actively adjust their metabolism to work properly within the matrix. Sometimes they go into a type of hibernation, a “persistent state”, in which they become resistant to many antimicrobials. In fact, the bacteria’s metabolic pathways must be active for antimicrobials to have an effect on them².

The periodontal disease treatment is commonly based on the oral hygiene and root debridement approaches³. Given the infectious nature of the periodontitis, local and systemic antibiotics can be administered as an adjunctive treatment to reduce or expel the microorganisms⁴. Among the localized therapeutic procedures, we found mouthwashes, subgingival irrigations, use of subgingival antibiotics and controlled drug delivery systems^{4,5,6,7,8}.

In recent years, the bacterial diseases related to dental implants were classified into two main types⁹: peri-implant mucositis, which involves only the soft tissues around the implant, and peri-implantitis, which presents the inflammation of the soft tissues and signs of bone loss.

A systematic literature review revealed that the non-surgical mechanical treatment can be effective in the treatment of peri-implant mucositis and that the use of antimicrobial mouthwashes would produce better treatment results. However, in the case of peri-implantitis, those treatments and the adjunctive use of chlorhexidine did not improve the clinical and microbiological parameters¹⁰. As regards the surgical treatment of peri-implantitis, another systematic review determined that surgical access associated with different implant surface decontamination methods and with the use of systemic antibiotics is not quite effective¹¹. Up to now, there is no reliable evidence suggesting one method as the most effective at treating peri-implantitis^{12,13}.

The pharmacological research on the treatment of diseases caused by the biofilm has changed directions in the last few years. It shifted from the antimicrobial effect of some substances to products that destroy the biofilm environment so that bacteria cannot survive. Then, a solution appeared, composed of sulfonic/sulfuric acids (HYBENX® Oral Tissue Decontaminant, EPIEN Medical, Inc.), which have a strong affinity for water, and with the characteristics of a contact desiccant.

In fact, this component (solution or gel) contains a concentrated aqueous mixture of hydroxybenzenesulfonic (37%) and hydroxymethoxybenzene (23%) acids, sulfuric acid (28%) and water (12%). The hydroxybenzenes are keratolytics, while the sulfonate group and the sulfuric acid are hygroscopic and denaturing. Both the liquid and gel have the same concentration. The chemical action is due to the interaction of the sulfate group with water molecules. The sulfate group, with the oxygen atoms on the external surface, has an internal

polar structure and carries a strong negative surface charge. The structure of the water molecules also has a significant polarity, which gives them a negatively charged surface and a positively charged one. The sulfate group tends to match its large negative surface with the many positive surfaces of the water molecules. These are reversibly bound to the sulfate surface through an electrostatic interaction known as *hydrogen bond*, where the positive charge on the surface of the hydrogen atoms of the water molecule is attracted to the negative charge of the surface of a group of oxygen atoms¹⁴ (Fig 1). Due to its chemical structure, the material is able to denature the biofilm matrix through a powerful desiccating action (topical). The biofilm desiccation results from a rapid subtraction of water from the matrix produced by the sulfonic and sulfuric acids, which make the matrix and the microorganisms coagulate and shrink. The biofilm material precipitates, contracts and separates from the tooth's surface (Fig 2). Since it allows for the eradication of the plaque microorganisms, the product facilitates the removal of the dental plaque¹⁵.

The topical application of the product for a few seconds is sufficient to destroy the pathogenic agents and the biofilm matrix, reducing the pain, the inflammation and the bleeding. As it is a selective agent, it does not produce any effect on the healthy tissues. Studies carried out with ion chromatography testing have shown that the properties of the material are those of a desiccant and not those of an acid (it is less erosive than citric acid (orange juice) and lactic acid (yogurt)). It does not damage the dental pulp nor the periodontal and peri-implant tissues, and it is completely biocompatible with these tissues^{14,15,16}. The product has also been approved for commercialization as a Class I medical device in the European Union, Scandinavia and Canada for professional dental use as an adjunctive focal irrigant intended to remove the dental plaque biofilm. Besides, it has been certified by the U.S. FDA for endodontic therapy.

Recent studies^{17,18} show the efficacy of the oral tissue decontaminant (HYBENX®) in the treatment of acute periodontal abscess and in the nonsurgical treatment of peri-implantitis without the need for systemic or local antibiotics. The infections were quickly resolved without complications and the periodontal and peri-implant pockets were reduced in a short period of time. A clinical case report¹⁹ assessed its efficacy in the treatment of chronic periodontitis in 11 adult patients. The *polymerase chain reaction (PCR)* technique was used to detect the microbial activity of *Porphyromonas gingivalis*, *Treponema denticola* and *Tannerella forsythia* before the treatment and 15 days after the use of the oral tissue decontaminant. After the treatment, a remarkable reduction in the amount of bacteria was observed. The average reduction was of approximately 99% in each of the red complex

bacteria and of about 96% in the total amount of bacteria. The authors conclude that the decontamination material is an effective adjunct to eradicate the bacterial load in the pockets of the patients affected by periodontitis^{17,19} and peri-implantitis¹⁸.

The aim of this report is to show the effect of the biofilm decontamination approach on the treatment of acute periodontal abscess and peri-implantitis.

CASE REPORTS

Case 1

A 52-year old woman showed acute periodontal abscess in the palatal root of the first maxillary molar with edema, suppuration, pain, minor mobility and increased probing depth (7.5 mm PD, 5.5 mm CAL)(Fig 3a).

By means of radiography, it was possible to observe vertical bone loss on the distal surface of the molar (Fig 3b). The decontaminant material was applied to the periodontal pocket without anesthetic. The material was removed after 30 seconds, rinsed with abundant sterile solution and aspirated. At the moment of the application, the patient reported moderate pain and it was possible to observe a white dehydrated area in the surrounding soft tissues that vanished after a few minutes (Fig 3c, d). Neither local nor systemic antibiotics were used, and scaling and root planing was not performed.

The following day, the patient reported symptom relief. After 15 days, it was possible to observe healing without edema or suppuration, and a rapid reduction in probing depth (5.5 mm PD, 5 mm CAL)(Fig 3e, f).

Case 2

A 54-year old woman showed generalized periodontal disease and peri-implantitis corresponding to the right mandibular premolars (Fig. 4a). The area presented inflammation and suppuration with increased probing depth, attachment loss and vertical bone loss as it can be observed in the preoperative radiography (6 mm PD and 4 mm CAL on the mesial surface of the first molar; 8 mm PD and 6 mm CAL on the mesial surface of the second premolar; and 14 mm PD and 12 mm CAL in the first premolar)(Fig. 4b). Flap surgery was performed to eliminate the implant of the first premolar (Fig. 4c) and the granulation tissue, and to decontaminate the implant of the second premolar and the periodontal defect of the molar (Fig. 4d). HYBENX® gel was used for the decontamination (Fig. 4e). The product was left

for 30 seconds, then rinsed with abundant saline solution and aspirated (Fig. 4f). A small dehydrated area was observed in the surrounding soft tissues, which vanished a few minutes after the tissue rehydrated itself (Fig. 4g). Scaling and root planing was performed only on the surface of the molar after the application of the desiccant material. Bone defects were regenerated using bone substitute of bovine origin (Geistlich Bio-Oss®, Princeton, NJ, USA) and resorbable collagen membrane (BioCollagen®, Bioteck, Arcugnano, Vicenza, Italy). Four months later, when evaluating the results, it was possible to observe bone formation in the explantation site and healing of the periodontal and peri-implant pockets (1.5 mm PD, 2 mm CAL on the mesial surface of the molar, and 3 mm PD, 3 mm CAL on the mesial surface of the implant)(Fig. 4h, i, j).

DISCUSSION

There are many infectious diseases, such as dental caries and periodontitis, which are caused by bacterial biofilms and not by planktonic germs¹.

It is well-known that, since the biofilm creates a protective niche around bacteria, it is very difficult to reach, reduce and eradicate them with local and systemic antibiotics. In fact, it has been already demonstrated that antiseptics are more effective when the biofilm is previously disorganized with hand or ultrasonic instruments^{20,21}.

Modern research has now shifted from the therapeutic objective of attacking the bacteria directly with antiseptics and antibiotics to that of destroying the biofilm structure, thereby causing death to all the bacteria living in it. The rapid and immediate dehydration and coagulation of the biofilm and the death of bacteria are due to the chemical properties of the material. The sulfuric and sulfonic groups, which have a strong negative charge, exert a powerful attraction on the water molecule in the biofilm matrix, which contains a positive charge on the surface due to the presence of hydrogen atoms.

The antibacterial effect and the safety of the oral decontaminant were successfully documented in the treatment of mouth ulcers, where the denaturation of their surface led to a rapid healing as it was described in a randomized trial¹⁶.

Recent studies showed the effectiveness of the oral tissue decontaminant material in the treatment of periodontal abscess¹⁷ and peri-implant lesions¹⁸, without using local or systemic antibiotics. The infections were quickly resolved without complications and the pockets were reduced in a short period of time.

A microbiological study¹⁹ reported that the decontaminant material is an effective substance to eradicate the red complex bacteria in the periodontal pockets of patients affected by moderate periodontitis.

On the basis of this knowledge, the material was tested in two specific clinical cases, an acute periodontal abscess and peri-implantitis. The treatment with the use of this material was proposed to the patients, who accepted after having been explained the process in detail and after having signed the corresponding informed consent in accordance with the Declaration of Helsinki (2008). The material was directly applied to the exposed root and to the surface of the implant. The healing was quick and there were no complications.

However, the most important feature of the local application of the decontaminant material for the bacterial biofilm treatment is that no local or systemic antibiotics were used in any of the cases. Avoiding the use of antibiotics in the treatment of periodontitis and peri-implantitis is a huge step forward in the treatment of bacterial infections, since the indiscriminate and repeated use of antibiotics can result in bacterial resistance, which puts patients' lives at risk²².

CONCLUSION

The biofilm desiccation approach seems to be a very promising technique for the treatment of acute periodontal abscess and peri-implantitis. As an additional advantage, this technique avoids the use of systemic and local antibiotics.

In any case, in order to evaluate the predictability of this treatment, longer controlled studies on more clinical cases are required.

CONFLICTS OF INTEREST

The authors reported no conflicts of interest related to this study.

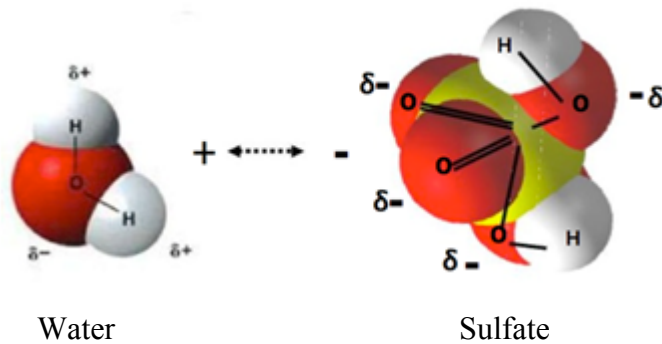
REFERENCES

1. Hall-Stoodley L, Costerton JW, Stoodley P. Bacterial biofilms: from the natural environment to infectious diseases. *Nature Reviews Microbiology* 2004;2:95-108.
2. Conlan BP, Rowe SE, and Lewis K. Persister Cells in Biofilm Associated Infections, pp 1-9 IN: *Biofilm-Based Healthcare Associated Infections*, VOL II, G. Donelli, Ed. Springer. 2014.
3. Greenwell H. Guidelines for periodontal therapy. Position Paper. *J Periodontol* 2001;72:1624-1628.
4. Mombelli A. Antibiotics in Periodontal Therapy. In Lang NP and Lindhe J. *Clinical Periodontology and Implant Dentistry*. 2008 Chapter 42; 882-897, 5th Edition.
5. Matesanz-Pérez P1, García-Gargallo M, Figuero E, Bascones-Martínez A, Sanz M, Herrera D. A systematic review on the effects of local antimicrobials as adjuncts to subgingival debridement, compared with subgingival debridement alone, in the treatment of chronic periodontitis. *J Clin Periodontol*. 2013;40:227-41.
6. Goodson JM, Haffajee A, Socransky SS. Periodontal therapy by local delivery of tetracycline. *J Clin Periodontol*. 1979;6:83-92.
7. Tonetti MS, Cugini MA, Goodson JM. Zero-order delivery with periodontal placement of tetracycline loaded ethylene vinyl acetate fibres. *J Periodontal Res*. 1990;25, 243-249.
8. Tonetti MS, Pini-Prato G, Cortellini P. Principles and clinical applications of periodontal controlled drug delivery with tetracycline fibers. *Int J Periodont Rest Dent*. 1994;14:421-35.
9. Quirynen M, Herrera D, Teughels W, Sanz M. Implant therapy: 40 years of experience. *Periodontol 2000*. 2014;66, 7-12.
10. Renvert S, Roos-Jansåker AM, Claffey N. Non-surgical treatment of peri-implant mucositis and peri-implantitis: a literature review. *J Clin Periodontol*. 2008;35(Suppl):305-15.
11. Claffey N, Clarke E, Polyzois I, Renvert S. Surgical treatment of peri-implantitis. *J Clin Periodontol*. 2008;35(Suppl):316-32.
12. Esposito M, Grusovin MG, Worthington HV. Treatment of peri-implantitis: what interventions are effective? A Cochrane systematic review. *Eur J Oral Implantol*. 2012;5 Suppl:S21-41.
13. Figuero E, Graziani F, Sanz I, Herrera D, Sanz M. Management of peri-implant mucositis and peri-implantitis. *Periodontol 2000*. 2014; 66, 255-273.
14. Basara M. *HYBENX® Oral Tissue Decontaminant Technical Dossier*. Design History Section. EPIEN Medical. December, 2014.


15. Costerton JW. *USC Dental Oral Microbial Biofilm Disruption Assays*. Contract Research, EPIEN Medical, Inc., 2007.
16. Porter SR, Al-Johani K, Fedele S, Moles DR. Randomised controlled trial of the efficacy of HYBENX in the symptomatic treatment of recurrent aphthous stomatitis. *Oral Diseases* 2009;15:155–161.
17. Pini-Prato GP, Magnani C, Rotundo R. Treatment of acute periodontal abscesses using the biofilm decontamination approach. A case report study *Int J Periodont Rest Dent* 2016;36:55-63.
18. Pini-Prato GP, Magnani C, Rotundo R. No surgical treatment of peri-implantitis using the biofilm decontamination approach. A case report study. *Int J Periodont Rest Dent* 2016. In Press.
19. Lauritano D, Girardi A, Carinci F. The efficacy of HYBENX® Oral Tissue Decontaminant for periodontal disease treatment: a case series study. *International Journal Of Advances In Case Reports*, 2015;2:405-408.
20. Marsh PD & Bradshaw DJ. Dental plaque as a biofilm. *J Ind Microbiol* 1995;15:169-175.
21. Anwar H, Strap JL, Costerton JW. Establishment of aging biofilms: possible mechanism of bacterial resistance to antibiotic therapy. *Antimicrobial Agents and Chemotherapy* 1992;36:1347-1351.
22. World Health Organization. Antimicrobial resistance: global report on surveillance. December 8th, 2014:1-257. At <http://www.who.int/drugresistance/documents/surveillancereport/en/>

FIGURES

Figure 1: Biofilm desiccation. Bacteria secrete a polysaccharide aqueous gel (matrix). Sulfate group, rapid water subtraction from the matrix (hydrogen union)

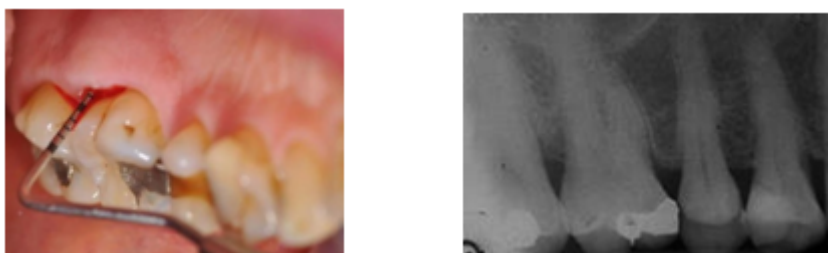


Figures 2a and b: Root surface (bacterial plaque) before (a) and after (b) the treatment with HybenX®. Under the dehydrated plaque, the surface is clean. Epien Medical, Inc.

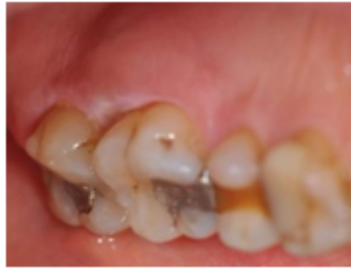
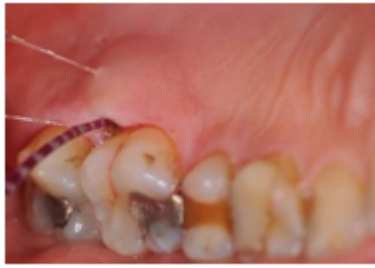
Case 1

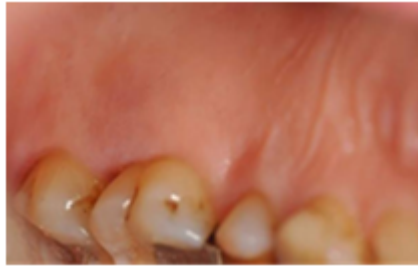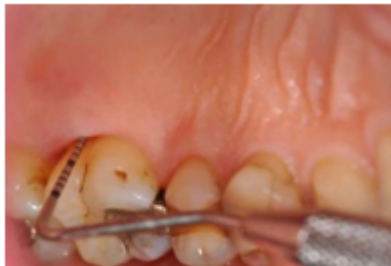Figures 3a and b: Clinical evaluation and radiography of an acute periodontal abscess (7.5 PD mm and 5.5 mm CAL)



Figures 3c and d: Application of the decontaminant material to the pockets for 30 seconds, without anesthesia or instrumentation. After the application, a white dehydrated area is observed on the soft tissues.



Figures 3e and f: Clinical evaluation 15 days after the treatment. The inflammation in the area was completely reduced (5.5 mm PD and 5 mm CAL)



Case 2

Figures 4a and b: Clinical and radiographic imaging of peri-implantitis in both implants. A periodontal pocket on the mesial surface of the molar is observed.

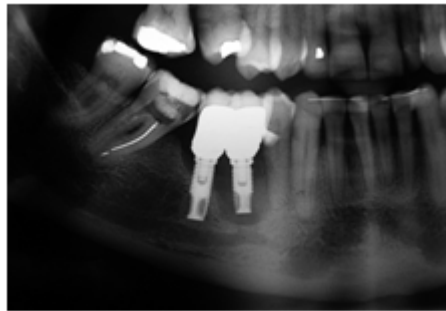
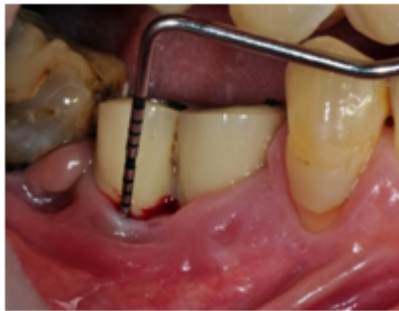

Figure 4c: Explantation of the implant located in the first premolar area, where a massive contamination is observed.

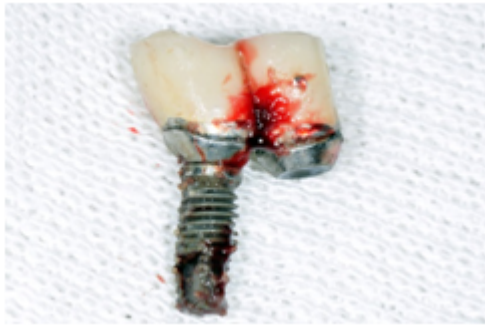

Figure 4d: Vertical bone loss in the implant of the second premolar once the granulation tissue was eliminated.

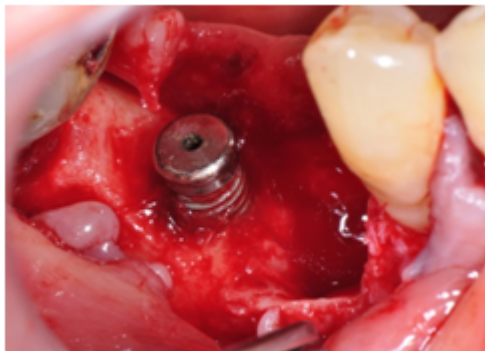
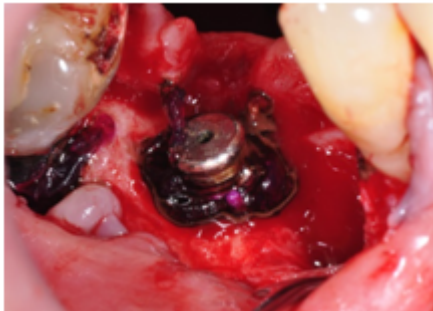


Figure 4e: Presentation of the oral tissue decontaminant material, liquid and gel.

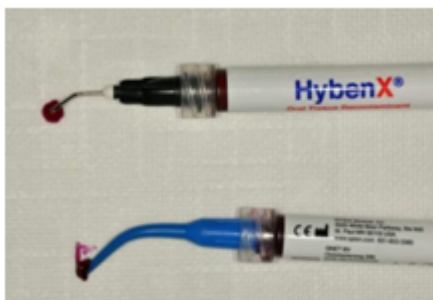

Figure 4f: Application of the gel to the surface of the implant and on the vertical defect of the mesial surface of the molar.



4g: Rinsing of the area with abundant saline solution and powerful aspiration. A small dehydrated area on the soft tissues is observed.

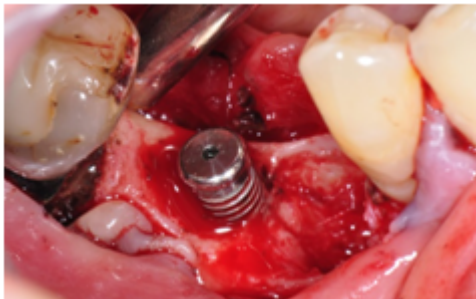


Figure 4h, i and j: Clinical and radiographic control 4 months after the surgery. A perfect healing of the peri-implant and periodontal defect is observed.

